

Case Report

Maturogenesis of a cariously exposed immature permanent tooth using MTA for direct pulp capping: a case report

Patel R, Cohenca N. Maturogenesis of a cariously exposed immature permanent tooth using MTA for direct pulp capping: a case report. © Blackwell Munksgaard, 2006.

Abstract – Successful direct pulp capping of cariously exposed permanent teeth with reversible pulpitis and incomplete apex formation can prevent the need for root canal treatment. A case report is presented which demonstrates the use of mineral trioxide aggregate (MTA) as a direct pulp capping material for the purpose of continued maturogenesis of the root. Clinical and radiographic follow-up demonstrated a vital pulp and physiologic root development in comparison with the contralateral tooth. MTA can be considered as an effective material for vital pulp therapy, with the goal of maturogenesis.

Rajiv Patel¹, Nestor Cohenca²

¹Endodontic Resident, Division of Surgical, Therapeutic and Bioengineering Sciences, University of Southern California School of Dentistry, Los Angeles, CA, USA; ²Department of Endodontics, School of Dentistry, University of Washington, Seattle, WA, USA

Key words: maturogenesis; direct pulp capping; mineral trioxide aggregate; vital pulp therapy; immature permanent tooth

Dr Nestor Cohenca, Department of Endodontics, University of Washington, POB 357448, Seattle, WA 98195-7448, USA
Tel.: +1 206 543 5044
Fax: +1 206 616 9085
e-mail: cohenca@u.washington.edu

Accepted 1 November, 2005

Apexogenesis is a vital pulp therapy procedure performed to encourage continued physiological development and formation of the root end; frequently used to describe vital pulp therapy performed to encourage the continuation of this process (1). This conservative approach is aimed at treating reversible pulpal injuries by preserving the vitality of the tissue and sealing the pulp in order to prevent further microbial contamination (2). Exposure of the dental pulp and periapical tissues to microorganisms results in the development of pulpal and periradicular pathosis. The role of microorganisms as the dominant etiologic factor for pulpal pathology has been well established (3, 4).

Immature teeth can be affected by caries or by trauma, which can influence the development and maturation of the root (5–7). If the pulp of an immature tooth becomes irreversibly inflamed or necrotic, the treatment can be difficult and unpredictable (7–11). Progress in understanding the molecular and cellular process during tooth development (2) and how they are mimicked during tissue repair (12, 13), offers the opportunity to assess

the biologic strength of vital pulp therapy (14). Therefore, our clinical goal should be to maintain pulp vitality and to be aware of factors that influence pulp healing (15).

The literature supports the potential of biocompatible materials such as mineral trioxide aggregate (MTA) to enhance pulpal repair by providing a good seal after direct pulp capping (16–20). MTA has been proved to be an effective pulp capping material with respect to its ability to improve reparative dentin formation by the stereotypic defensive mechanism of early pulpal wound healing (21–25).

Recently, the term maturogenesis gained new attention and has been defined as the physiological root development, not restricted to the apical segment (26). The continued deposition of dentin occurs throughout the length of the root, providing greater strength and resistance to fracture. A case report is presented in which the vitality of the pulp was maintained utilizing MTA as a direct pulp capping material allowing physiological root development.

Case report

A 9-year-old Caucasian girl was referred by her dentist for evaluation and root canal therapy of her lower left first premolar. The patient's medical history was non-contributory. No spontaneous pain was reported by the patient and her main complaint was sensitivity to cold and sweets. The pain and sensitivity were localized on the left side in the lower jaw. Clinical examination revealed gross occlusal caries on her lower left first premolar with no signs of extraoral or intraoral swelling or sinus tract formation. The lower left first premolar tested negative to percussion and palpation tests and the mobility was within normal limits. Pulp vitality tests using tetrafluoroethane (Endo-Ice, Hygenic Corp., Akron, OH, USA) showed a normal positive response, with no lingering sensation. The adjacent teeth also responded positive and within normal limits to cold stimulation. Radiographic findings revealed caries in close proximity to the mesial pulp horn and an undeveloped root with a wide-open apex and no evidence of periradicular pathology. In order to establish a baseline for follow-up, the status of root development was compared with the contralateral lower right first premolar at the same appointment.

Based on the results of clinical and radiographic examination, the pulpal status of the lower left first premolar was determined as vital with reversible inflammation due to caries. The initial treatment plan included the removal of the carious lesion and clinical evaluation of the pulp exposure. Vital pulp therapy including either direct pulp capping or partial pulpotomy with mineral trioxide aggregate was planned for the anticipated pulp exposure. As the patient was a minor, informed consent was obtained from her father.

Following administration of local anesthesia, the tooth was isolated with rubber dam. A dental-operating microscope was used to enhance visual-

ization and caries removal was performed using a no. 4 sterile round bur on a low speed handpiece with copious water irrigation. Caries indicator (Seek, Ultradent, South Jordan, UT, USA) was used to ensure removal of all infected dentin and prevent undue removal of affected dentin. After removal of caries, exposure of pulp horns with moderate bleeding was observed (Fig. 1). A sterile cotton pellet moistened with saline was used to apply moderate pressure to the exposed pulp for 5 min and hemostasis was achieved. Sodium hypochlorite (5.25%) was then utilized as a rinse for 2 min to disinfect the surgical exposure and the dentin (Fig. 2). The cavity preparation was again gently rinsed with sterile water to remove the superficial clot and debris. The cavity was lightly dabbed with a moist pellet to remove the excess moisture.

Mineral trioxide aggregate (MTA; Pro Root MTA, Dentsply Tulsa, Tulsa, OK, USA) was mixed according to the manufacturers instructions and a 1–2 mm thick layer of MTA was placed over the exposure site and adjacent dentinal surface with a

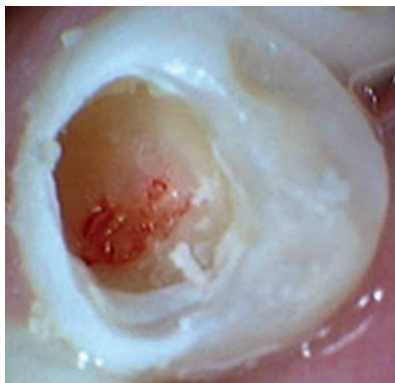


Fig. 1. Pulp exposure presenting with moderate bleeding.

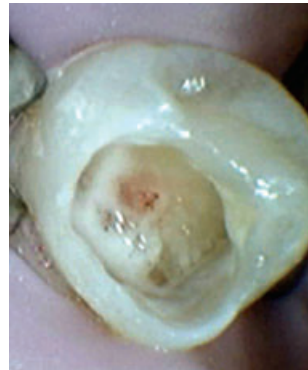

Fig. 2. Disinfection of exposure site by rinsing with 5.25% sodium hypochlorite.

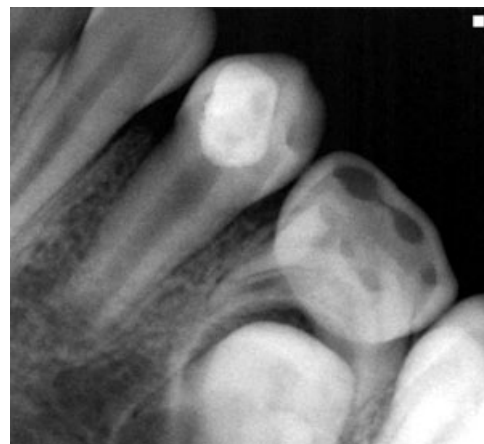

Fig. 3. Immediate postoperative periapical radiograph showing pulp capping with MTA, cotton and temporary filling material.

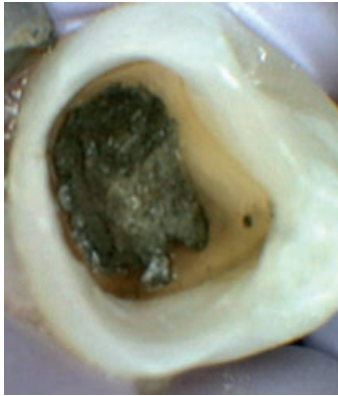

Fig. 4. Verification of the setting of MTA at 48 h.

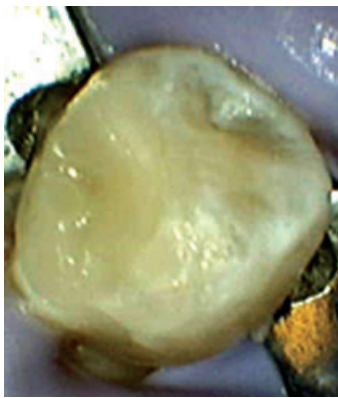

Fig. 5. Final coronal restoration with composite.

plastic carrying instrument. The mix was then padded with a moist cotton pellet to ensure optimum contact of MTA with exposed pulp tissue. A moist cotton pellet was then placed over the MTA and the rest of the cavity was restored with temporary filling material (Tempit, Centrix Inc, Shelton, CT, USA; Fig. 3). The patient was scheduled after 48 h to evaluate the setting of MTA and also to follow up on any abnormal symptoms.

At the 48 h follow-up appointment the patient was asymptomatic. Under rubber dam isolation and the use of a dental-operating microscope, the provisional restoration and cotton pellet were removed and the complete setting of the MTA was confirmed by probing its surface (Fig. 4). A light-cured microfilled hybrid resin composite restoration (Gradia™ Direct, Alsip, IL, USA) was incrementally placed over the MTA and the crown was permanently sealed and restored (Fig. 5).

The patient was scheduled for a 3-month follow-up in order to evaluate root development and to monitor for any signs or symptoms. The parents were asked to call and inform the dental office if the patient reported any pain or discomfort.

Four months later, clinical examination revealed an intact restoration and absence of any abnormal

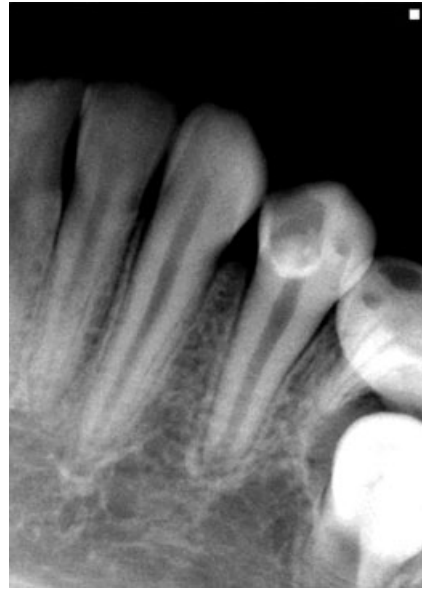

Fig. 6. Follow-up periapical radiograph at 4 months presenting with continued root development.

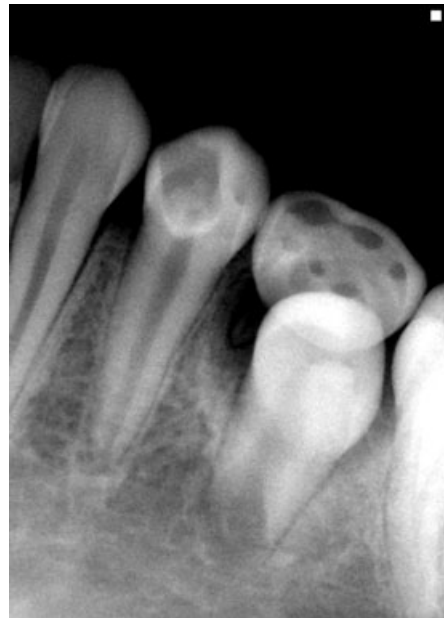

Fig. 7. Follow-up periapical radiograph at 11 months showing maturogenesis of the root.

signs or symptoms. The lower left first premolar tested positive and normal to thermal pulp stimulation with cold. A periapical radiograph showed continued development and maturation of the root (Fig. 6).

At 11 months, no abnormal findings were observed and the pulp tested within normal limits. A normal developmental radiolucent area with a corticated margin surrounding the periapex was

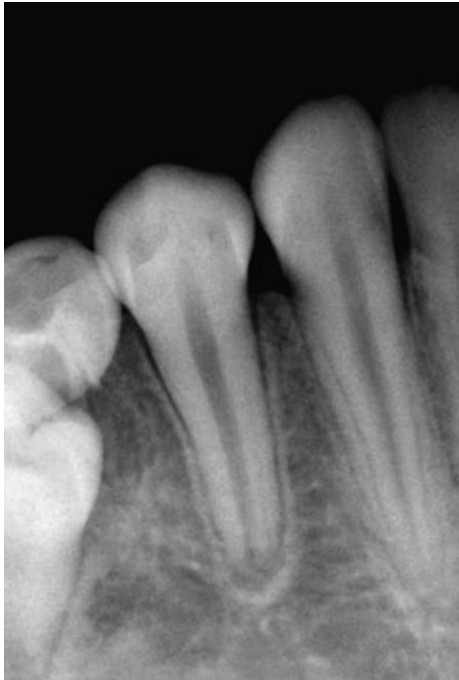

Fig. 8. Periapical radiograph of contralateral premolar comparing root development at 11 months postoperative.

observed for the lower left first premolar as well as for the contralateral lower right first premolar. Root maturation was observed to have significantly progressed when compared with the preoperative radiographs and was similar to the status of root development and maturation of the contralateral premolar (Figs 7 and 8). The patient was scheduled for routine recall visits every 6 months. The parents were informed about the potential need for root canal therapy in case of signs and symptoms.

Discussion

Vital pulp therapy and regeneration of necrotic pulps has become an alternative conservative treatment option for young permanent teeth with immature roots (2, 8, 10, 17). The aim of vital pulp therapy is to preserve and protect the reversibly inflamed pulp tissue from additional injury and to facilitate its healing and repair while maintaining vitality (2).

An immature tooth with early irreversible pulp involvement presents with thin divergent or parallel dentinal walls. This clinical situation may cause difficulty in cleaning and obturation of the root canal system, thus affecting the long-term outcome of the treatment. Maintenance of vitality will exploit the full potential of the pulp for dentin deposition and will produce a stronger mature root that is better able to withstand fracture (7).

Much debate continues between the advocacies of pulp capping vs pulpotomy, but it is generally accepted that an attempt must be made to preserve pulp vitality in immature teeth with exposed pulps. Seltzer and Bender have suggested that a mechanically exposed young pulp has a better prognosis because of its repair potential in the absence of contamination when compared with carious exposures which have chronic inflammation secondary to microbial invasion (27). Factors which influence treatment decisions when encountering teeth with pulpal exposure include the degree of infection and inflammation in the pulp space, rather than the size or duration of pulp exposure (20). For traumatic exposures in young asymptomatic immature teeth, a direct pulp cap or partial pulpotomy are the treatments of choice. In contrast to traumatic exposures, carious process can lead to marked changes within the pulp-dentine complex, which can vary considerably depending on the severity of the disease and the age of the pulp. It is generally agreed that larger carious exposures have a poor prognosis due to a more severely inflamed pulp, risk of necrosis and bacterial contamination (28). Careful case selection and treatment planning is critical for a better outcome of treatment rendered.

The histologic extent and degree of inflammation cannot be accurately predicted clinically. Studies have demonstrated that optimum hemorrhage control is essential for successful outcome of direct pulp capping regardless of the material used (29, 30). Sodium hypochlorite (NaOCl) in concentrations 2.5–5.25%, in addition to being ideal for hemorrhage control when placed on an exposed pulp, also provides aseptis, chemical amputation of the blood clot and fibrin and removal of damaged cells and operative debris from the mechanical exposure and subjacent pulp. Optimum hemostasis will also help achieve the goal of bacteriostatic seal. Other studies showed that sodium hypochlorite does not impair or retard the cellular healing of exposed pulps and is not inhibitory to the biologic mechanisms of odontoblastoid cell or dentin bridge formation (31, 32). In addition, it can be used for removal of residual microbial flora, which can be a major deterrent in healing of exposed pulp.

MTA has been compared with various capping materials including calcium hydroxide, which is the historical panacea of endodontic therapy (33). The deficiencies of calcium hydroxide include poor adherence to dentin, inability to form a long-term seal against bacterial microleakage and a porous dentinal bridge formation (18). However, despite these issues, some studies reported that partial pulpotomy of cariously exposed immature teeth with calcium hydroxide have a long-term success rate of 93% (34, 35). In contrast, pulps capped with

MTA consistently demonstrated complete tubular bridge formation and lack of pulpal inflammation (16–18). The dentinogenic effects of MTA can be attributed mainly to its sealing ability and biocompatibility with subjacent tissues, which facilitates restoring normalcy to the pulpal and periradicular tissues. In cases where a permanent seal is placed over the direct pulp capping material and the therapy proved successful during the follow-up evaluation, there is no further need for barrier verification or immediate endodontic treatment.

Clinical and radiographic evaluation at 3-month intervals is stressed after maturogenesis therapy so as to assess pulp vitality and progression of root development. Current vitality tests still depend on neurological stimulation and its reliability on immature teeth is considered questionable (15). The radiographic diagnosis of periapical pathology may also become difficult in immature teeth because of the normal radiolucency of the developing root sheath which occurs apically as the root matures. Comparison of root formation with the contralateral teeth should be always performed to evaluate treatment outcome. Hopefully, the future of vital pulp therapy will witness the development of more tissue engineering and biomimetics for tissue regeneration after injury.

Conclusion

The use of MTA has been proven clinically and by various *in vivo* and *in vitro* studies to allow pulp healing after injury. Immature teeth, destined for endodontic therapy will be imparted an opportunity to complete maturation with conservative management. However, the treatment outcome for carious exposed pulps is questionable and in case of failure, pulp revascularization and apexification should be considered.

References

- American Association of Endodontists. Glossary of endodontic terms, 7th edn. Chicago: American Association of Endodontists; 2003.
- Tziafas D, Smith AJ, Lesot H. Designing new treatment strategies in vital pulp therapy. *J Dent* 2000;28:77–92.
- Kakehashi S, Stanley HR, Fitzgerald RJ. The effects of surgical exposures of dental pulps in germ-free and conventional laboratory rats. *Oral Surg Oral Med Oral Pathol* 1965;20:340–9.
- Moller AJ, Fabricius L, Dahlen G, Ohman AE, Heyden G. Influence on periapical tissues of indigenous oral bacteria and necrotic pulp tissue in monkeys. *Scand J Dent Res* 1981;89:475–84.
- Arens DE. Treatment of the incompletely formed tooth. *J Indiana Dent Assoc* 1977;56:15–20.
- Tenca JI, Tsamtouris A. Continued root end development: apexogenesis and apexification. *J Pedod* 1978;2:144–57.
- Webber RT. Apexogenesis vs apexification. *Dent Clin N Am* 1984;28:669–97.
- Windley W III, Teixeira F, Levin L, Sigurdsson A, Trope M. Disinfection of immature teeth with a triple antibiotic paste. *J Endod* 2005;31:439–43.
- Shabahang S, Torabinejad M. Treatment of teeth with open apices using mineral trioxide aggregate. *Pract Periodontics Aesthet Dent* 2000;12:315–20; quiz 322.
- Banchs F, Trope M. Revascularization of immature permanent teeth with apical periodontitis: new treatment protocol? *J Endod* 2004;30:196–200.
- Camp J, Barret E, Pulver F. Pediatric endodontics: endodontic treatment for the primary and young, permanent dentition. In: Cohen S, Burns RC, editors. *Pathways of the pulp*, 8th edn. St Louis: Mosby, Inc; 2002. p. 797–844.
- O’Kane S, Ferguson MW. Transforming growth factor beta s and wound healing. *Int J Biochem Cell Biol* 1997;29:63–78.
- Magloire H, Joffre A, Bleicher F. An *in vitro* model of human dental pulp repair. *J Dent Res* 1996;75:1971–8.
- Fuks AB. Current concepts in vital primary pulp therapy. *Eur J Paediatr Dent* 2002;3:115–20.
- Love RM. Effects of dental trauma on the pulp. *Pract Periodontics Aesthet Dent* 1997;9:427–36; quiz 438.
- Ford TR, Torabinejad M, Abedi HR, Bakland LK, Kariyawasam SP. Using mineral trioxide aggregate as a pulp-capping material. *J Am Dent Assoc* 1996;127:1491–4.
- Torabinejad M, Chivian N. Clinical applications of mineral trioxide aggregate. *J Endod* 1999;25:197–205.
- Faraco IM Jr, Holland R. Response of the pulp of dogs to capping with mineral trioxide aggregate or a calcium hydroxide cement. *Dent Traumatol* 2001;17:163–6.
- Holland R, de Souza V, Murata SS, Nery MJ, Bernabe PF, Otoboni Filho JA, Dezan Junior E. Healing process of dog dental pulp after pulpotomy and pulp covering with mineral trioxide aggregate or Portland cement. *Braz Dent J* 2001;12:109–13.
- Fong CD, Davis MJ. Partial pulpotomy for immature permanent teeth, its present and future. *Pediatr Dent* 2002;24:29–32.
- Andelin WE, Shabahang S, Wright K, Torabinejad M. Identification of hard tissue after experimental pulp capping using dentin sialoprotein (DSP) as a marker. *J Endod* 2003;29:646–50.
- Saidon J, He J, Zhu Q, Safavi K, Spangberg LS. Cell and tissue reactions to mineral trioxide aggregate and Portland cement. *Oral Surg Oral Med Oral Pathol Oral Radiol Endod* 2003;95:483–9.
- Menezes R, Bramante CM, Letra A, Carvalho VG, Garcia RB. Histologic evaluation of pulpotomies in dog using two types of mineral trioxide aggregate and regular and white Portland cements as wound dressings. *Oral Surg Oral Med Oral Pathol Oral Radiol Endod* 2004;98:376–9.
- Moghaddame-Jafari S, Mantellini MG, Botero TM, McDonald NJ, Nor JE. Effect of ProRoot MTA on pulp cell apoptosis and proliferation *in vitro*. *J Endod* 2005;31:387–91.
- Parirokh M, Asgary S, Eghbal MJ, Stowe S, Eslami B, Eskandarizade A, Shabahang S. A comparative study of white and grey mineral trioxide aggregate as pulp capping agents in dog’s teeth. *Dent Traumatol* 2005;21:150–4.
- Weisleder R, Benitez CR. Maturogenesis: is it a new concept? *J Endod* 2003;29:776–8.
- Seltzer S, Bender IB. Pulp capping and pulpotomy. In: Seltzer S, Bender IB, editors. *The dental pulp*, 3rd edn. Philadelphia: J.B. Lippincott Company; 1984. p. 281–302.
- Ricketts D. Management of the deep carious lesion and the vital pulp dentine complex. *Br Dent J* 2001;191:606–10.

29. Hafez AA, Cox CF, Tarim B, Otsuki M, Akimoto N. An *in vivo* evaluation of hemorrhage control using sodium hypochlorite and direct capping with a one- or two-component adhesive system in exposed nonhuman primate pulps. *Quintessence Int* 2002;33:261–72.
30. Matsuo T, Nakanishi T, Shimizu H, Ebisu S. A clinical study of direct pulp capping applied to carious-exposed pulps. *J Endod* 1996;22:551–6.
31. Cox CF, Bogen G, Kogel HM, Ruby JD. Repair of pulpal injury by dental materials. In: Hargreaves KM, Goodis HE, editors. *Seltzer and Bender's dental pulp*. Chicago: Quintessence Publishing; 2002. p. 325–43.
32. Kato M, Kidokoro S, Kuroso K. A study on the amputation of pulp using sodium hypochlorite. *Jpn J Pediat Dent* 1978;16:107–16.
33. Aeinehchi M, Eslami B, Ghanbariha M, Saffar AS. Mineral trioxide aggregate (MTA) and calcium hydroxide as pulp-capping agents in human teeth: a preliminary report. *Int Endod J* 2003;36:225–31.
34. Mejare I, Cvek M. Partial pulpotomy in young permanent teeth with deep carious lesions. *Endod Dent Traumatol* 1993;9:238–42.
35. Cvek M, Lundberg M. Histological appearance of pulps after exposure by a crown fracture, partial pulpotomy, and clinical diagnosis of healing. *J Endod* 1983;9:8–11.